

# Treatment of Snoring and Obstructive Sleep Apnea using CAUP (Coblation® Assisted Upper-Airway Procedures)



**Author – Magne Tvinneim, MD, PhD, ENT-Surg.**  
Bergen Soevn Center, Bergen, Norway & Eurosleep United Kingdom, Denmark, Norway and Serbia&Montenegro

## TECHNIQUE GUIDE

### Procedure Overview

CAUP (Coblation® Assisted Upper-Airway Procedures) is a multistage treatment concept where you can choose one, several or all steps to treat your patient depending on clinical need. ReFlex Ultra™ 55 Wand can be used for all steps.

### CAUP

- Turbinates
- Palate
  - Incision
  - Volume reduction by:
    - Upwards palatal channeling
    - Uvular resection & channeling
- Pillar reduction
  - Downwards channeling (anterior & posterior)
- Tonsillar channeling
- Tongue base reduction

### Patient Preparation

- 1 For patient comfort, apply Xylocain Gel 2%, 5 - 10 ml into the patient's mouth for 15 - 20 minutes. This is to reduce the gag reflex during surgery.
- 2 A mixture of Xylocain/Adrenalin 2% and 0.5 ml Solu-Cortef (or other steroid solution) is prepared in a 5 ml syringe with thin needle and injected into the soft palate in 3 - 4 injections on each side of the mid-line.
- 3 Wait for 5 minutes.

### Equipment Preparation

- 1 Insert the ReFlex Ultra 55 Wand into the connector end of the Patient Cable. Align the raised dot on the Wand handle with the black dot on the Patient Cable.
- 2 Set the Controller power level to 5 or 6, depending on the surgeon preference as judged by resistance during channeling (ablation) in the soft palate.

### Coblation-Channeling® Technique

Before each insertion, dip the Wand tip in saline solution to ensure formation of the plasma field. The intracellular fluid within the tissue will be sufficient to maintain the plasma field during channeling. Space out multiple channels to avoid creating overlapping lesions.

### Palate Incision

- 1 The patient is best seated in an upright position in an ENT examination chair, opposite the surgeon.
- 2 Put an emesis basin in the patient hand, and in the other hand a bent tongue depressor (spatula). Patients often feel more comfortable if they are able to regulate the pressure on the tongue.
- 3 Using the Ablation pedal, activate the ReFlex Ultra 55 Wand tip to create an incision 1 - 2 cm long, made at approximately 45 degrees upward angle at the lateral rim of the soft palate (Figure 1). The dissection is obtained by gentle strokes of the Wand tip while stabilizing the soft palatal rim by using a surgical forceps. It is of great importance to dissect through the posterior pillar, thus leaving as wide of a transversal opening as possible. By just making one incision, a maximum of untouched mucosal lining is left undamaged, thus reducing the tendency for retraction and mucosal scarring as well as salivary gland damage that can cause mouth dryness.

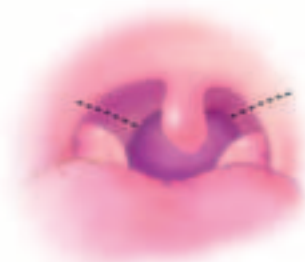


Figure 1

## Upwards Palatal Channeling

- 1 Insert the ReFlex Ultra 55 Wand through the incised area.
- 2 Channeling is made upwards to an area 1/2 - 1 cm below the hard palate.
- 3 Three channels are usually preferred on each side of the midline (Fig 2), and the ReFlex Ultra 55 Wand is activated for 8 - 12 seconds, depending on the amount of soft palatal tissue.

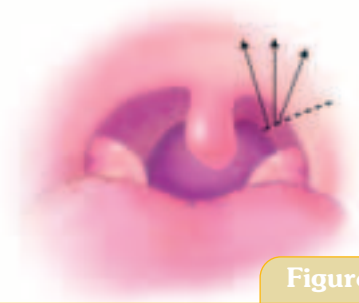


Figure 2

## Uvular Resection & Channeling

- 1 This process can be indicated and is carried out after an additional depletion of local anaesthetics.
- 2 Insert the wand through the uvula so that you can see the tip of the wand on the opposite side. To minimize bleeding, create a lesion by applying energy for 10 seconds to coagulate the uvula artery at the site where you intend to resect the uvula.
- 3 Start with transversal resection of the distal 1 - 2 cm by gentle strokes from side to side with the tip of the ReFlex Ultra 55 Wand. Preferably a surgical forceps is used for stabilizing the uvula, while the patient depresses the tongue.
- 4 Ablate 1 or 2 upwards channels superior of the base of Uvula for 6-10 seconds (Figure 3).

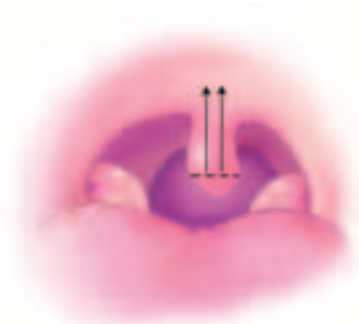


Figure 3

## Pillar Reduction

- 1 Broad anterior as well as posterior pillars may participate in pharyngeal narrowing by causing a small transversal diameter.
- 2 Reduction is then carried out by downwards channeling with the Reflex Ultra 55 Wand, for 8-10 seconds (Figure 4).
- 3 The rim of the incision is stabilized by a surgical forceps, and the patient depresses the tongue during the procedure.
- 4 1 - 2 channels are recommended in each pillar.

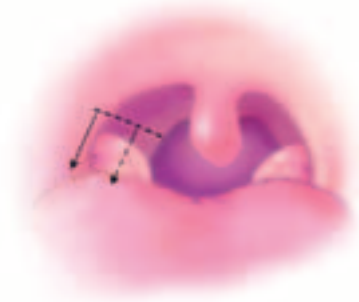


Figure 4

## Tonsillar Channeling

- 1 Anaesthetise the tonsil using local anaesthetics, 1 - 2 ml in each upper tonsillar pole, where the Wand penetrates the capsule.
- 2 To obtain sufficient access to the lateral area of the pharynx where the tonsils are situated, it is recommended that the surgeon hold the tongue depressor in one hand and the electrode in the other.
- 3 Insert the Reflex Ultra 55 Wand in the tonsillar tissue, 3-5 downwards channels are made in each tonsil for 10 - 12 seconds (Figure 5).  
It is important to note that the direction of the electrode should be strictly vertical, thus avoiding getting closer to the lateral - posterior pharyngeal wall than 1/2 cm. This is necessary to avoid vessels and nerves. Channeling is performed as far down in the tonsils as can be performed in a controlled manner.

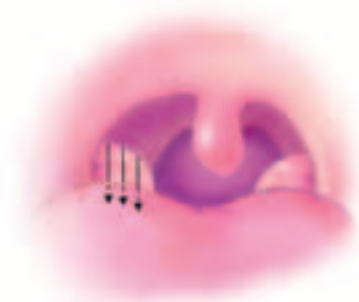


Figure 5

## Post-operative Instructions

- 1 Observe the patient for a few hours and give plenty of ice cubes and cold drinks to control swelling and bleeding. Cold meals and cold drinks for 24 hours.
- 2 Postoperative pain and swelling is well controlled by Voltarol. Antibiotics may be indicated.



**Headquarters:**  
ArthroCare Corporation  
680 Vaqueros Avenue  
Sunnyvale, CA 94085-3523 USA  
Toll Free: (800) 797-6520  
Tel: (408) 736-0224  
Fax: (408) 736-0226

**International:**  
ArthroCare Europe AB  
Baggensgatan 25  
SE-111 31 Stockholm Sweden  
Tel: +46 8 546 172 00  
Fax: +46 8 546 172 39  
E-mail: info@arthrocare.se  
www.arthrocareENT.com